

# Treatment Based on the Neuromuscular Concept: A Case Report

*Tsuguyasu Sasaki, DDS, FICCMO*

## **ABSTRACT:**

This report presents a case in which evaluation of the mandibular position and occlusal reconstruction were performed based on the neuromuscular concept, and good outcome was obtained with use of Golden Vertical as a parameter of occlusal vertical dimension in addition to use of K7 for evaluation of jaw movements and EMG.

## ***Patient's information***

The subject was a 64-year-old female home care helper.

Her chief complaint was an unfixed bite position, tooth abrasion, and being unable to smile properly.

The patient presented on February 14, 2012 with the chief complaint of esthetic impairment due to tooth attrition and loss of intercuspal position.

The patient had been aware of bruxism and clenching since her 20's. She was able to eat without any problems but she had multiple habitual occlusal positions.

Clicking was noted when opening or closing the temporomandibular joint, but she had no pain or trismus. The patient had chronic purulent apical periodontitis of tooth #19 and #19-21 bridge detachment. The patient had lost teeth #18, 29, 30 and 31 and had not been using her partial dentures for a few months as they had broken. Remarks: Reflux gastroenteritis. The patient often experienced work-related shoulder stiffness.

(*Figure 1*) Intraoral and frontal facial images taken prior to initiation of treatment with the neuromuscular technique after completion of tooth #19 infected root canal treatment.

Marked dental attrition caused the occlusal plane to be slanted significantly to the left. The patient chewed with her left side due to loss of teeth on the right side. When smiling, this meant that the amount of inter-occlusal clearance made the left side appear larger than the right side. The center of the mandible deviated approximately 2mm to the left compared with the maxilla. The patient had been diagnosed with bruxism over 30 years ago.

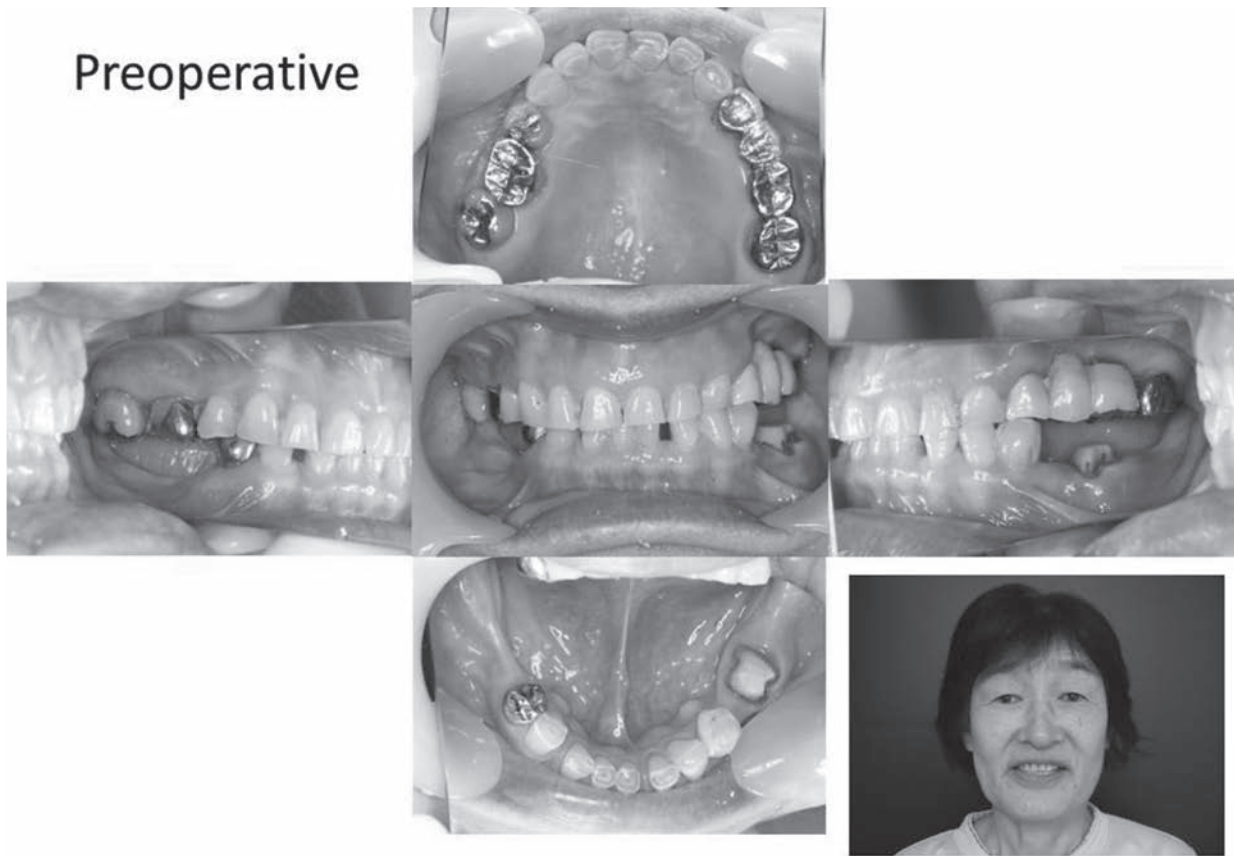


Figure 1

## Preoperative Scan 9 & 10

Scan 9

Scan 10

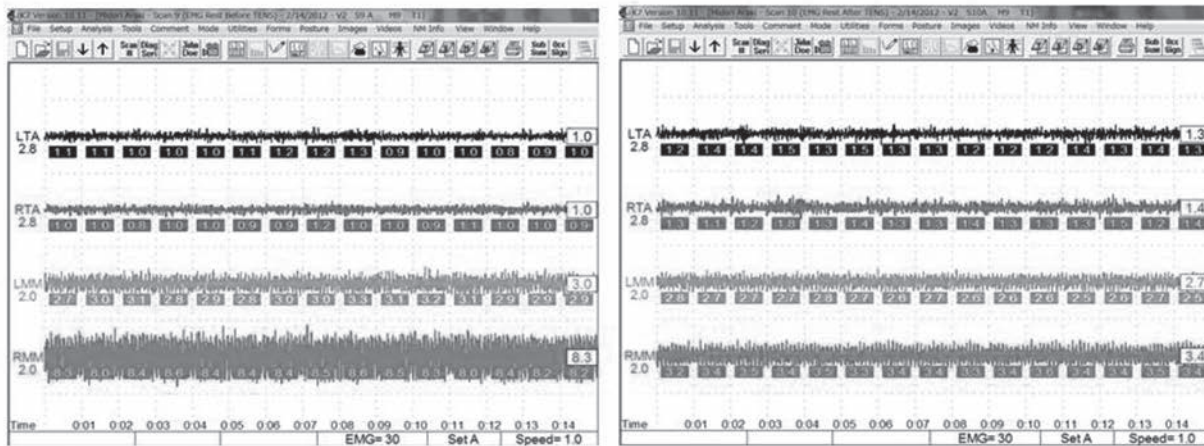


Figure 2

## Preoperative Scan 2 & 11

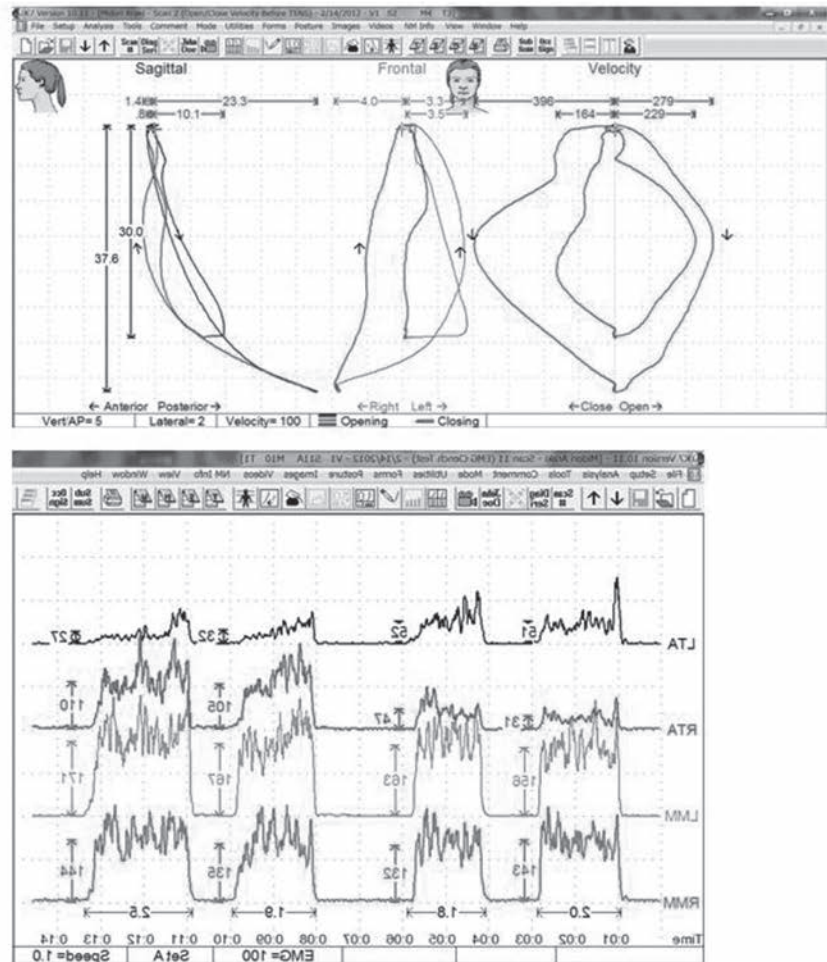


Figure 3

She may have had no lingual habits because she had no arch discrepancy. The occlusal plane was slightly diagonal relative to the hamular incisive papilla (HIP) plane and was unlikely to treat the mandible. The above mentioned points suggested that the jaw position may have originally been similar to muscular position, thus scanning was initiated. (Figure 2)

The fact that no TMJ symptoms were observed despite the patient complaining of shoulder stiffness means that it is unfortunate that only four channels were taken.

There were no problems with oral aperture or opening closing speed.

Scan2 involved taking scans of gently opening and closing at a normal speed and fast and wide opening and closing of the mouth. While clicking was observed when the patient opened and closed

her mouth fast and wide, there were no problems with oral aperture or speed. Moreover, in the final stage of treatment, the scanning method was altered so that two scans of the subject opening and closing her mouth fast and wide could be taken. (Figure 3)

The fact that a physiological mandibular rest position existed on the habitual mouth opening and closing path suggested that the mandible was in the muscular position antero-posteriorly. However, the loss of lower right teeth and dental attrition meant that the intercuspal position deviated 1.6 mm to the left. Furthermore, the intercuspal position was found to be unclear. (Figure 4)

The patient's intercuspal position was unclear. The patient had VI of 10.9 mm due to abnormal attrition.

# Preoperative Scan 5

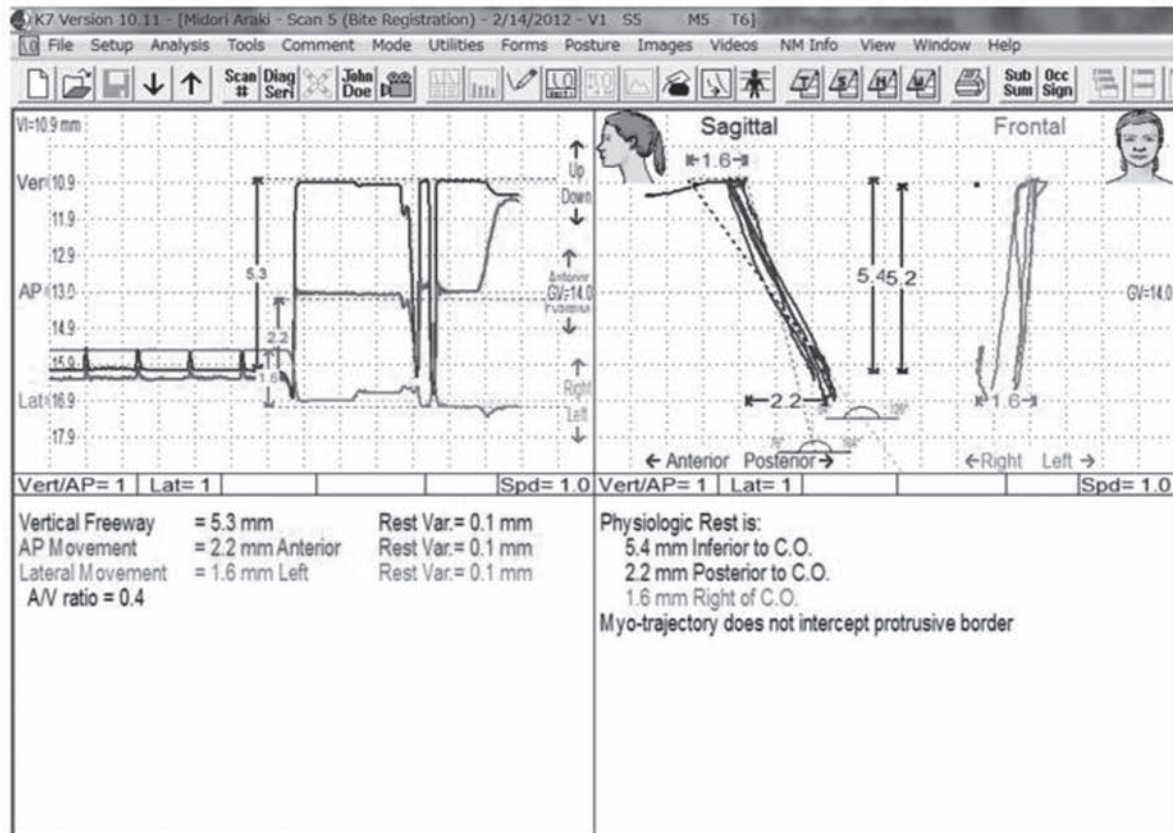


Figure 4

Bilateral anterior displacement of the TMJ articular disc was suspected due to bilateral TMJ clicking on opening and closing of the mouth.

## Treatment

The author did not use MRI to examine the state of both TMJ articular discs, thus we could not definitively determine whether they were restored. However, because the patient had no discomfort such as TMJ pain or trismus, the author decided to determine a treatment plan at a later date while observing her progress by creating a neuromuscular position that took into account the TMJ environment such as the position of the articular disc and state of the mandible.

An orthosis was not used because the patient had no TMJ symptoms. First, temporary crown

replacement was conducted with the previous jaw position.

One fixed intercuspal position was decided upon, occlusion was elevated and crown height was restored. Normal tegmentum was affixed to the anterior teeth and the provisional restoration was manufactured. The occlusal plane was parallel to the bipupillary line. Directly after the provisional restoration setting, the patient complained that her jaw became tired while eating and she could not bite through fibrous vegetables. Her jaw may have become tired because her muscles had not adjusted to the occlusal elevation. I therefore advised her to practice 5 × 5 stretches proposed by IKEDA. This gradually led to a reduction of jaw tiredness. I explained to the patient that it was difficult for her to bite through vegetables because it was a provisional



restoration and she was not used to the new intercuspal position. The patient was also subjectively aware that she had not yet let go of her habit of chewing with her poor habitual occlusal position. I advised her to undergo rehabilitation that involved chewing with the TMJ hinge in the new intercuspal position. (Figure 5)

We confirmed that correct muscular position had been achieved with the provisional restoration. (Figure 6)

After confirming that the patient's chief complaints had been addressed with the provisional restoration, we moved onto the final restoration. For financial reasons, hard resin facing and full cast crowns were selected. As bruxism remained despite occlusal elevation, metal was used for the occlusal surfaces. (Figure 7)

In accordance with the patient's request, I was unable to use dental implants to supplement lost

teeth. Because partial dentures exert suppression displacement on mucous membranes and teeth, it is difficult to transfer correct occlusion onto a model. Therefore, impression taking was conducted using MCL trays. (Figure 8)

Maxillary central incisor width was set at 7.6 mm, so the distance between cement-enamel junction of the mandibular and maxillary central incisors was set at 15.9 mm based on the LVI Golden Vertical. (Figure 9)

After setting the final restoration, the patient found it easier to bite through foods but complained that she could still not bite through fibrous vegetables such as pak choi. Scan 8 revealed that the patient was chewing so that the masticatory end-point deviated from the intercuspal position. It appeared that this made it difficult for her to chew because her cuspids were rising too quickly, resulting in the lingual side slope of the canines being ground down

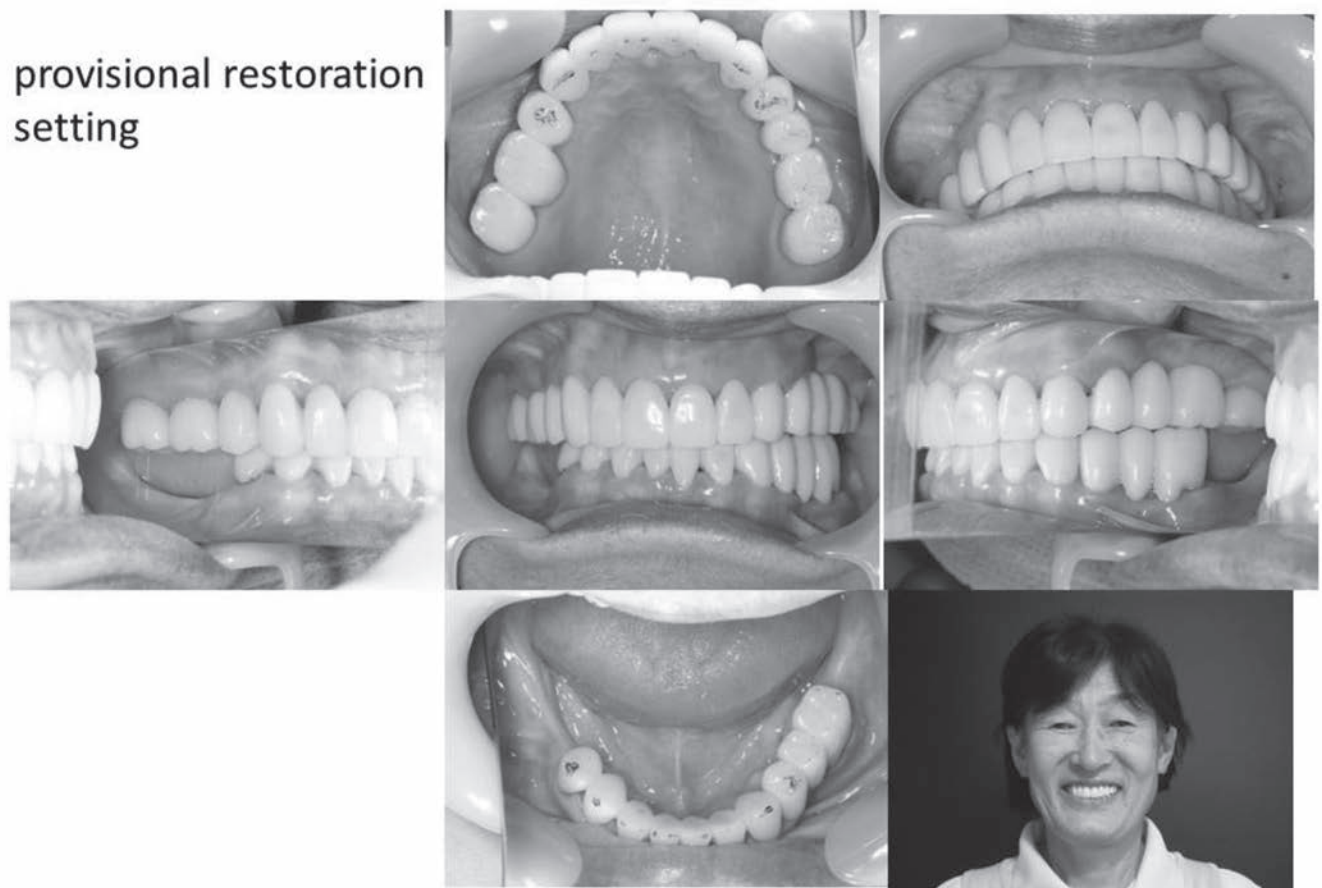


Figure 5

## Scan 5 with provisional restoration

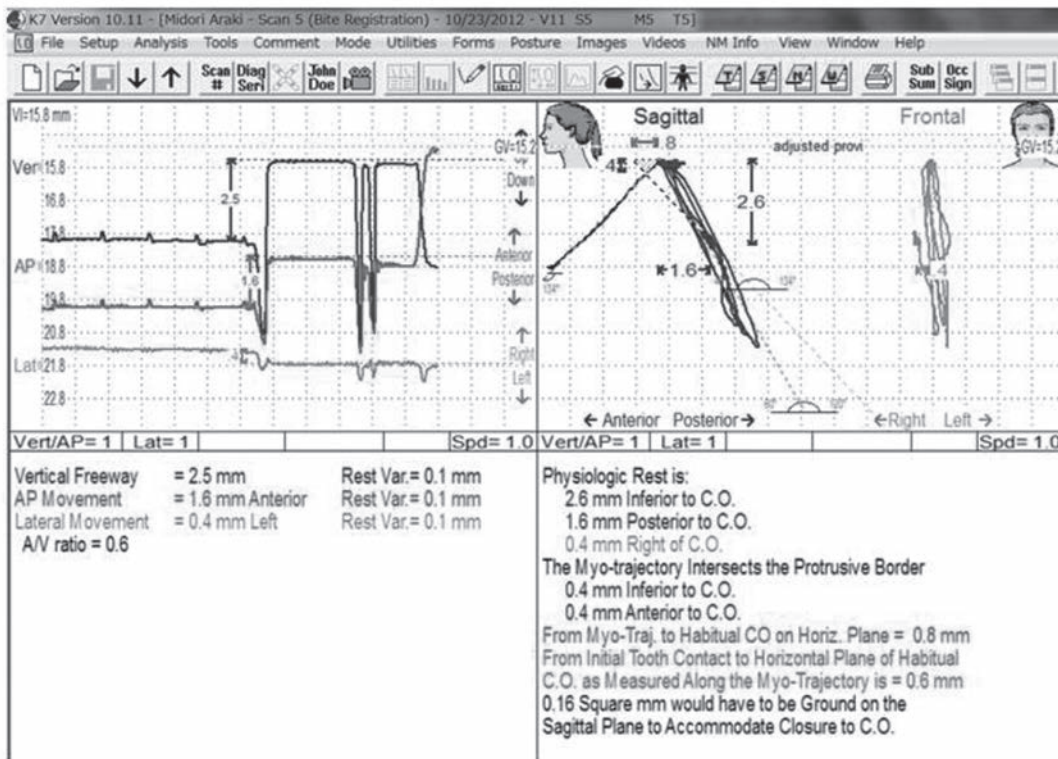


Figure 6

## Setting final crowns and bridges

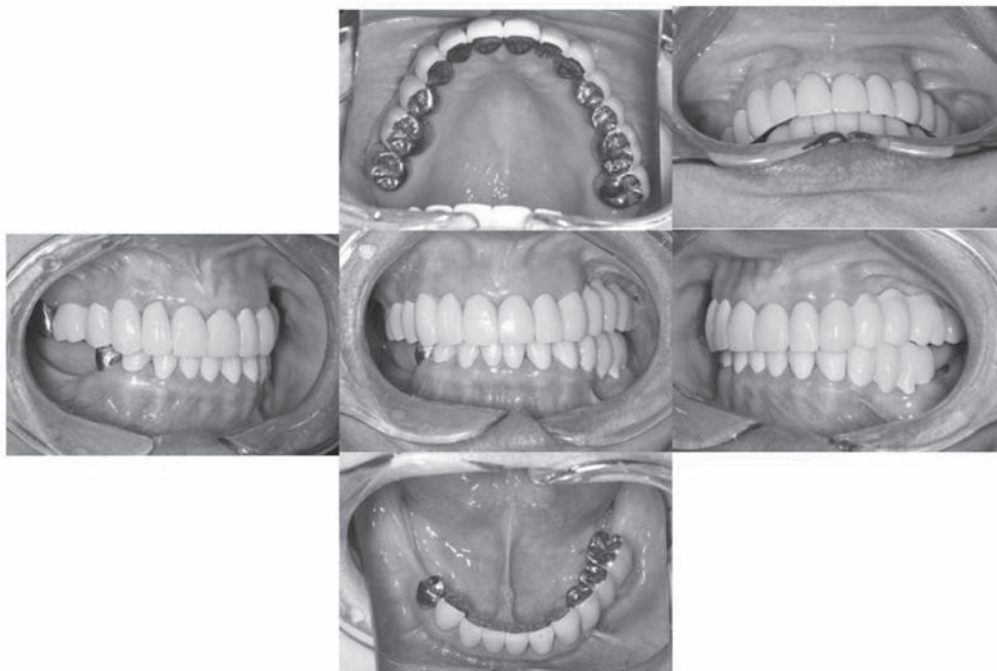


Figure 7

so that the patient had sequential open bite. We were therefore able to solve the problem. However, the patient's reflux gastroenteritis meant that she sometimes took her dentures out to eat. When she took her dentures out, her chewing pattern would still deviate from the intercuspal position. Therefore the author advised her to make sure that her dentures are inserted when she eats. (Figure 10)

Before grinding of tooth #23 lingual side slope, the patient sometimes deviated from the intercuspal position when chewing on the right side. (Figure 11)

Scans taken 3 months postoperatively.

No significant changes in each muscle compared with scans 9 and 10. (Figure 12)

It is clear that muscle position has been achieved compared with Scan 5.

Although the set intercuspal position still horizontally deviates physiologically 0.4 mm to the left from mandibular rest position, the author consid-

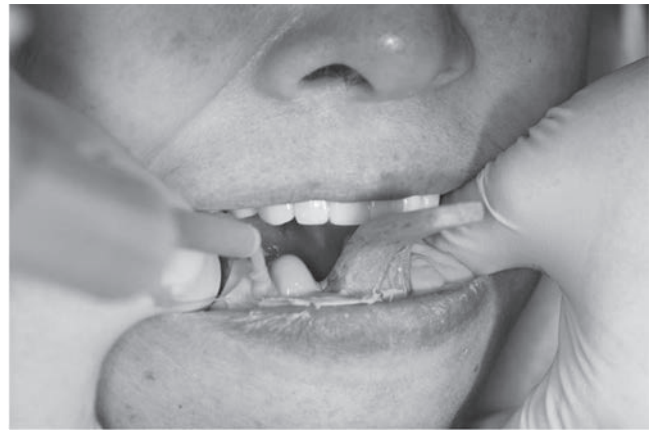

Figure 8

ered this within the permissible range because the patient had no symptoms. (Figure 13)

Left and right amount of lateral movement is nearly identical. Oral aperture and opening speed are both normal. The patient can open and close her mouth more smoothly than before treatment. (Figure 14)

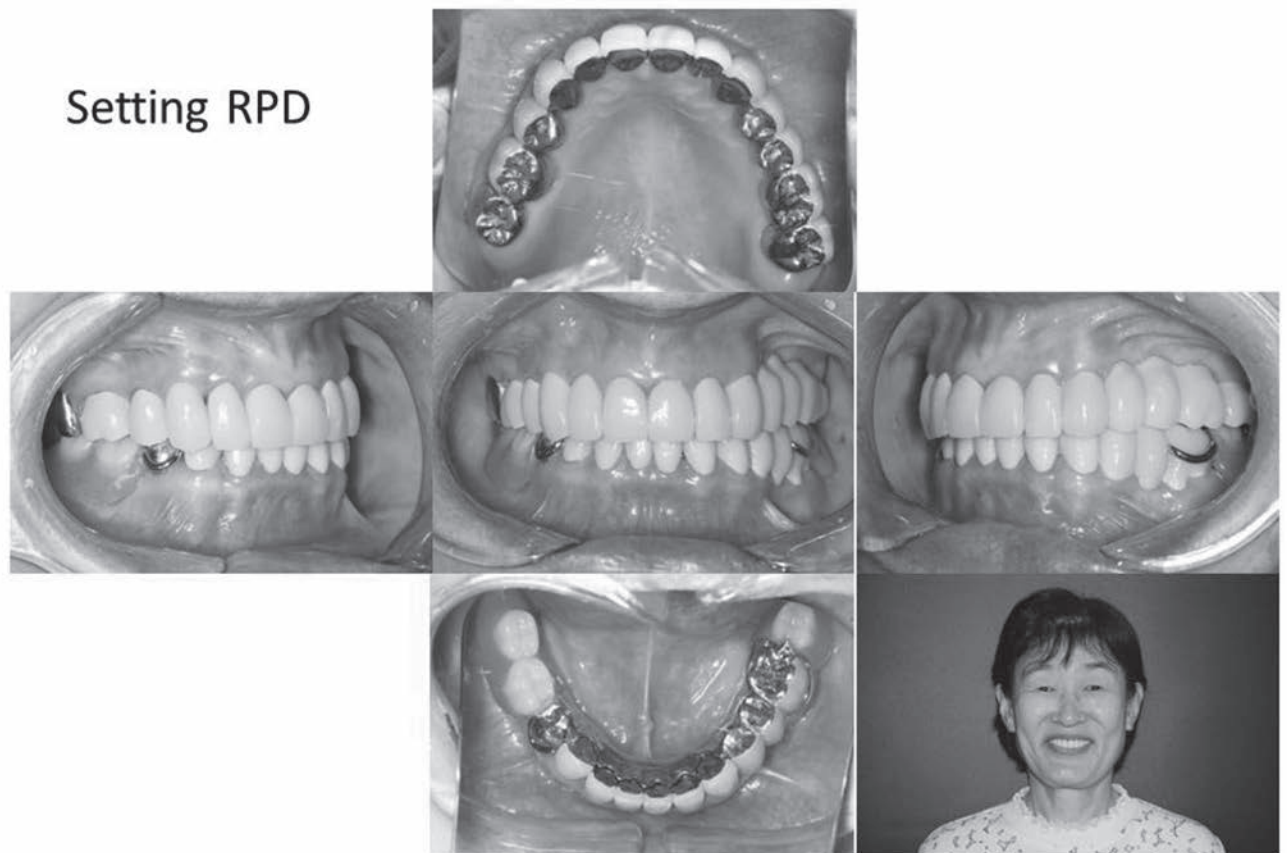


Figure 9



## Sequential open bite.

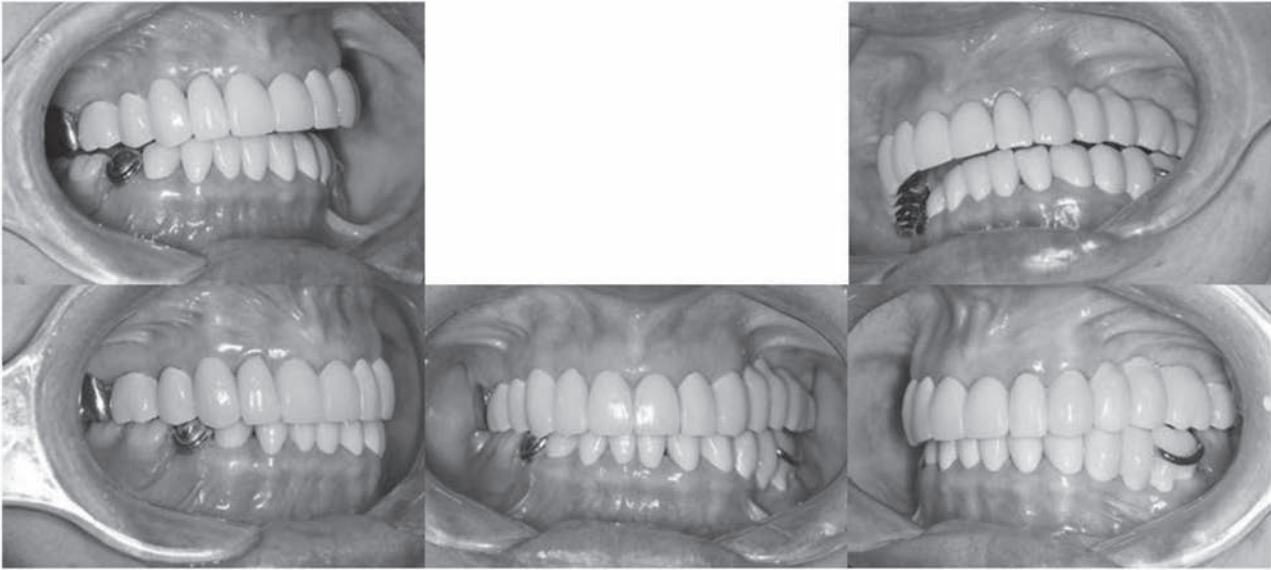
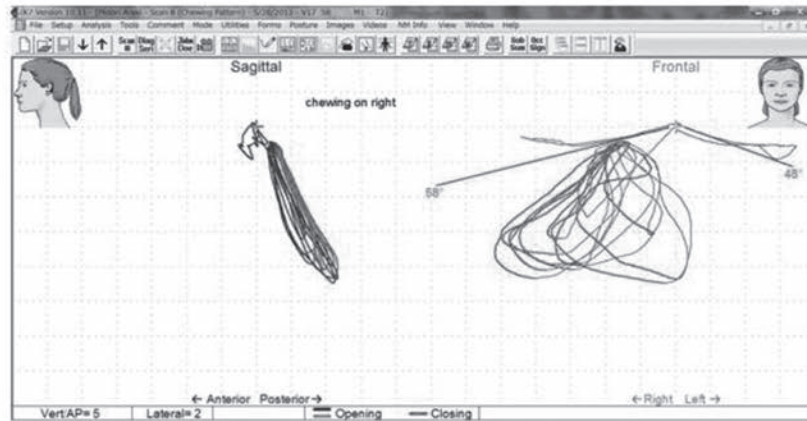


Figure 10

## Scan 8

Before adjustment



After adjustment

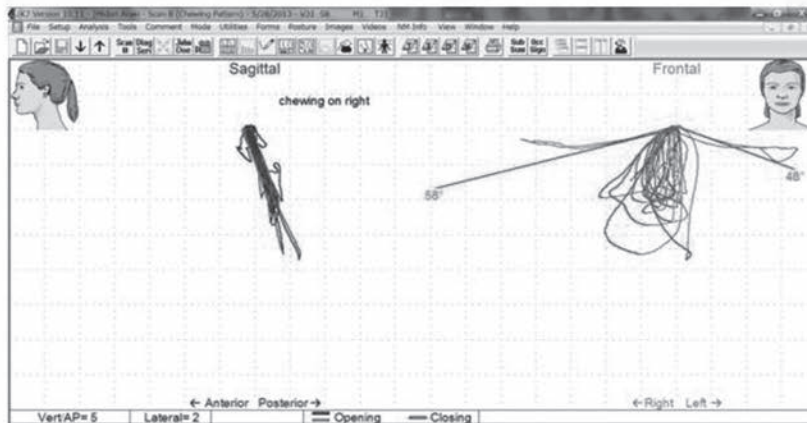


Figure 11



# Scans 9 & 10 taken 3 months postoperatively

Scan 9

Scan 10




Figure 12

# Scans 5 taken 3 months postoperatively

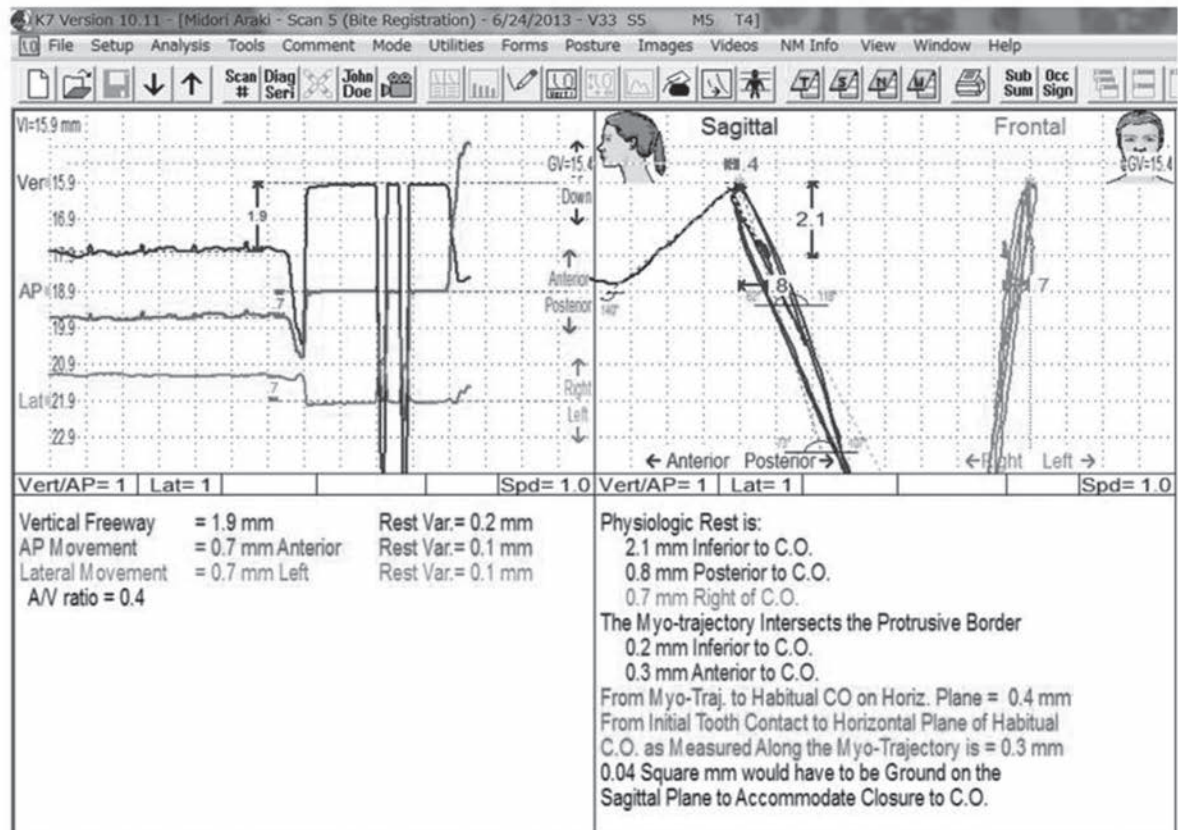


Figure 13

## Scans 2 & 13 taken 3 months postoperatively

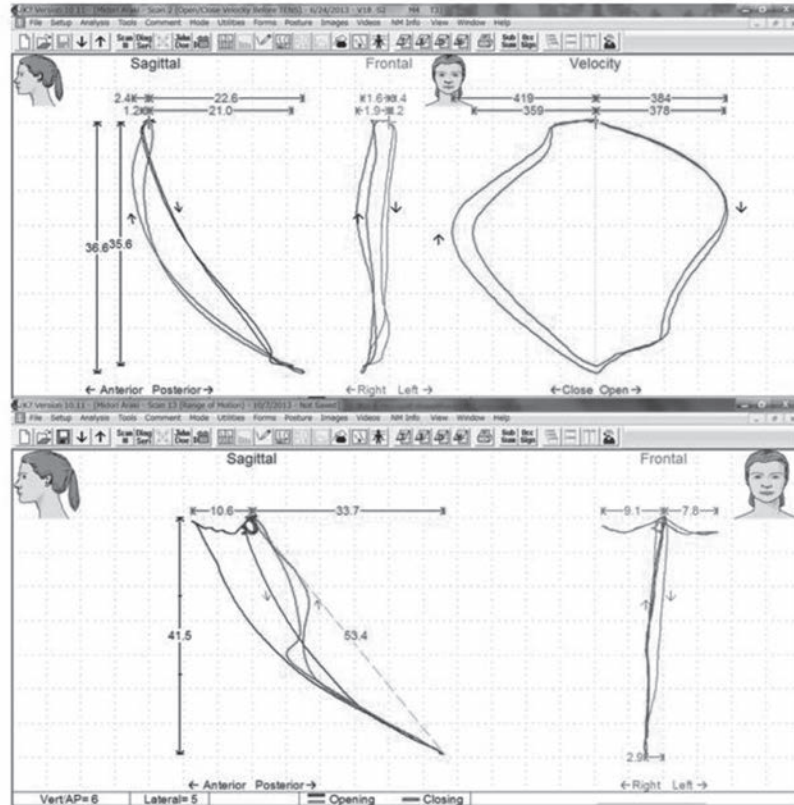


Figure 14

## SCAN 11

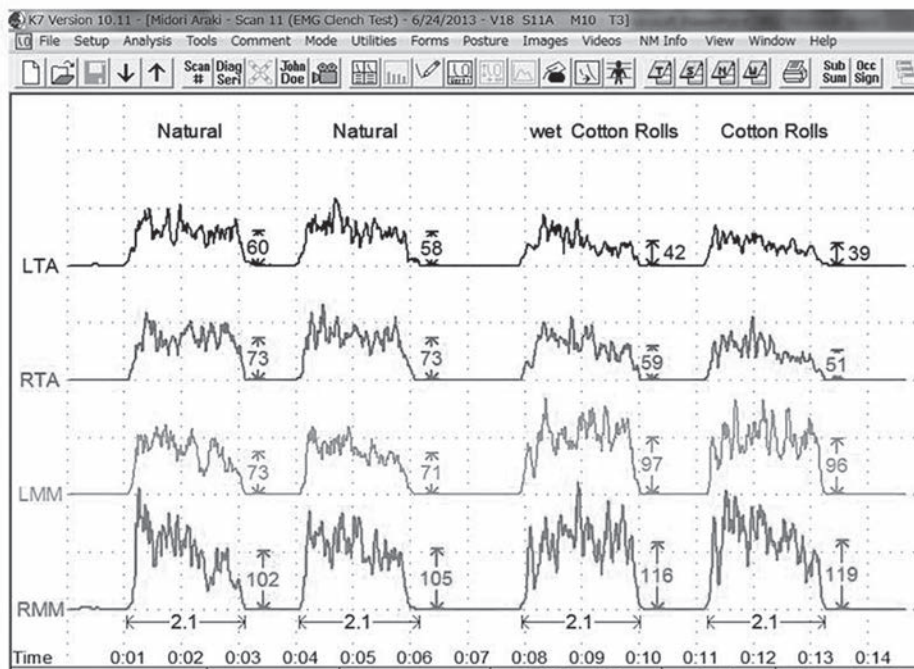
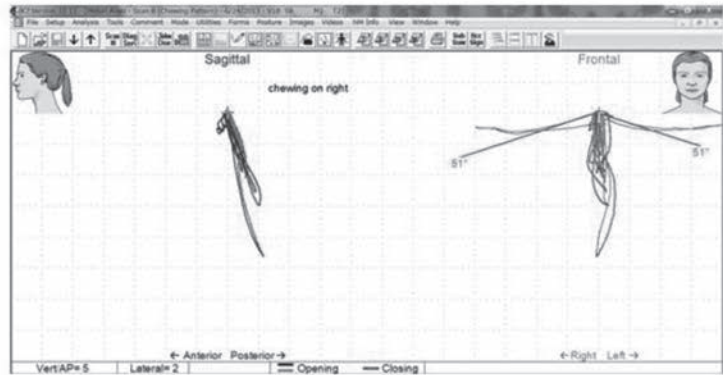


Figure 15



## Scans 8 taken 3 months postoperatively

Chewing on right



Chewing on left

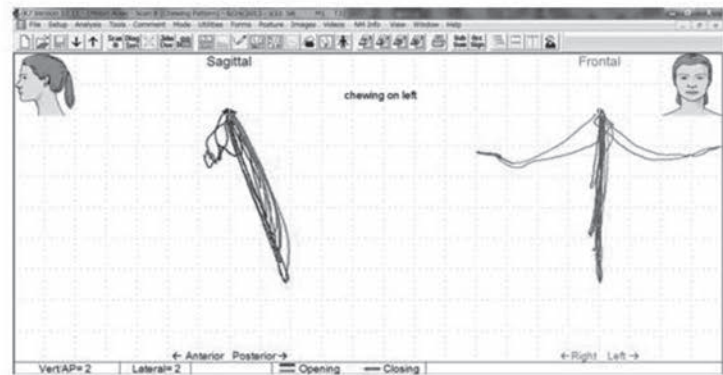
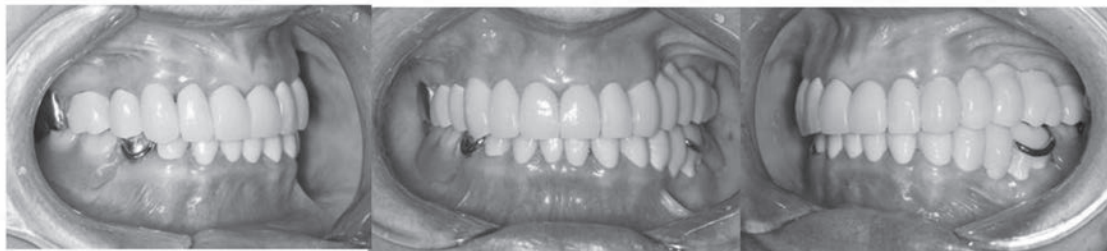
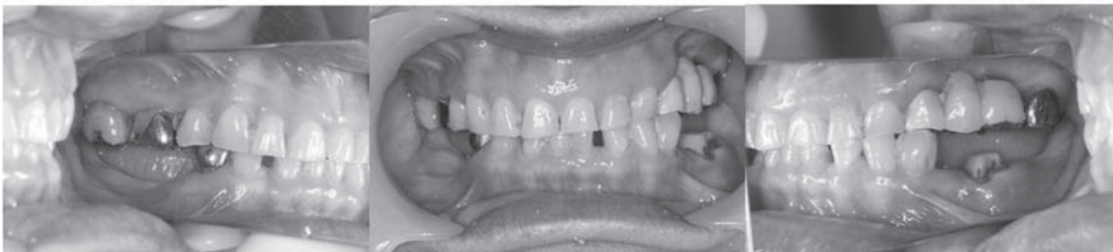
Figure 16

## Preoperative & postoperative oral images

Preoperative



Postoperative

Figure 17



## Preoperative & postoperative facial images

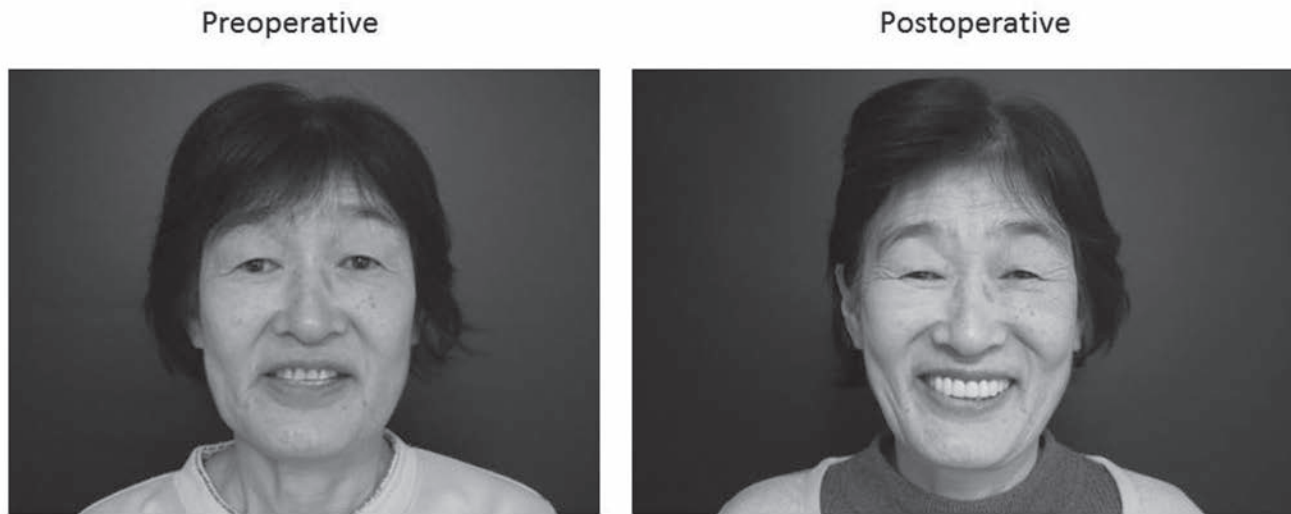


Figure 18

According to the patient, it was easier to chew without interposing a cotton role. (Figure 15)

The end-point of the masticatory cycle converges at one point in both left and right sides. (Figure 16)

### DISCUSSION:

The mandible was guided approximately 1 mm to the right so that the center of the upper and lower jaws almost matched. It was also guided approximately 1 mm posteriorly and elevated 5 mm. The occlusal plane was parallel to both the bipupilar line and HIP plane. Because of the lost teeth in the lower right molars, the patient had a habit of chewing on her left side, which caused abnormal dental attrition and mandibular dental attrition and mandibular deviation. Therefore, the author advised the patient to make sure that she always wore her dentures and explained that it was important to also chew on her right side. (Figure 17)

There are preoperative and postoperative facial images. (Figure 18) It appears that marked esthetic recovery has been achieved using the golden vertical distance rule. Function has also

improved compared with that before treatment. Thus, the author was able to conduct treatment based on the data, as explained earlier. This suggests that full mouth reconstruction using the neuromuscular concept is beneficial not only for cosmetic improvement but for stomatognathic functional improvement.

### References

1. Ikeda M, Takamatsu H, *Basics and Clinical Practice of the neuromuscular concept – in search for integration of esthetics and function*, Kumamoto: KKC Text Book Editing Committee, 65-117
2. Yamashita A, Yatani H, Mitani H, Kuboki T, *The newest physiologic occlusion and treatment of TMD*, Tokyo; Quintessence